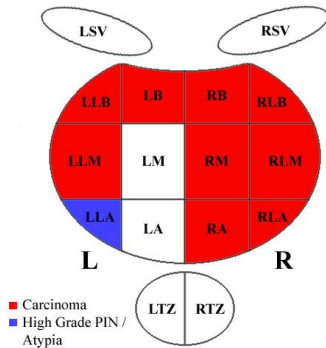


Brown & Associates
 medical laboratories, L.L.P.

2525 W. Bellfort St., Ste. 120 Houston, TX 77054
 Tel: 713.741.6677 Fax: 713.748.5860

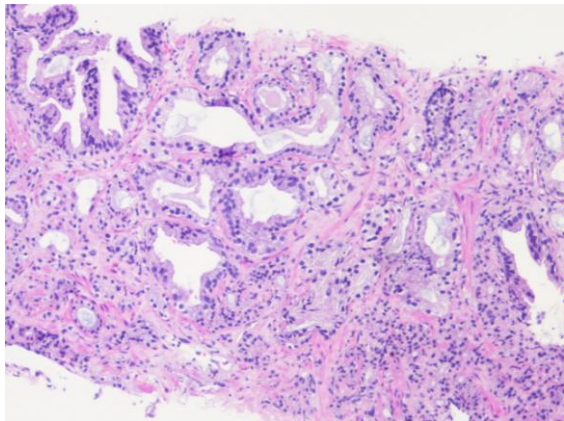
Surgical Pathology Report

Accession Number SW07-3	DOB/Age/Sex 12/08/1934 (Age: 72) M	Page 1
Patient Name Duck, Donald	Patient ID # None Provided	Collected 05/22/2007
Requesting Physician/Report Sent To UNKNOWN		Received 05/23/2007
Facility ABC Urology Center		Reported 05/24/2007



Received in formalin and entirely submitted as: (nails / rv)

Block	Specimen Source	Number Pieces	Measurement
A.	LLB	1	0.7 cm.
B.	LLM	1	0.7 cm.
C.	LLA	1	1.0 cm.
D.	LB	1	0.7 cm.
E.	LM	1	0.8 cm.
F.	LA	1	0.6 cm.
G.	RB	1	0.9 cm.
H.	RM	1	0.5 cm.
I.	RA	1	0.5 cm.
J.	RLB	1	0.9 cm.
K.	RLM	1	0.7 cm.
L.	RLA	1	0.2 cm.



Final Diagnosis:

A. Left lateral base, biopsy:

- Prostatic parenchyma with adenocarcinoma, combined score 7 (3+4).
- There is one focus of carcinoma which measures 2.5 mm in length and occupies 50% of the biopsy.

B. Left lateral mid, biopsy:

- Prostatic parenchyma with adenocarcinoma, combined Gleason score 6 (3+3).
- One focus of carcinoma is present which measures 1.5 mm in length and occupies 20% of the biopsy.

C. Left lateral apex biopsy:

- Prostatic parenchyma with focal glandular atypia, not diagnostic for malignancy.

D. Left base, biopsy:

- Prostatic parenchyma with adenocarcinoma, combined Gleason score 6 (3+3).
- One focus of carcinoma is present which measures 1 mm in length and occupies 10% of the biopsy.
- Perineural extension of carcinoma is identified.

E. Left mid, biopsy:

- Benign prostatic parenchyma.

F. Left apex, biopsy:

- Benign prostatic parenchyma.

G. Right base, biopsy:

- Prostatic parenchyma with adenocarcinoma, combined Gleason score 7 (4+3).
- One focus of carcinoma is present which measures 7 mm in length and occupies 100% of the biopsy.
- Focal high grade prostatic intraepithelial neoplasia.

H. Right mid, biopsy:

- Prostatic parenchyma with adenocarcinoma, combined Gleason score 7 (4+3).
- One focus of carcinoma is present which measures 5.5 mm in length and occupies 100% of the biopsy.

I. Right apex, biopsy:



Brown & Associates
 medical laboratories, L.L.P.

2525 W. Bellfort St., Ste. 120 Houston, TX 77054
 Tel: 713.741.6677 Fax: 713.748.5860

Surgical Pathology Report

Accession Number SW07-3	DOB/Age/Sex 12/08/1934 (Age: 72) M	Page 2
Patient Name Duck, Donald	Patient ID # None Provided	Collected 05/22/2007
Requesting Physician/Report Sent To UNKNOWN		Received 05/23/2007
Facility ABC Urology Center		Reported 05/24/2007

- Prostatic parenchyma with adenocarcinoma, combined Gleason score 7 (4+3).
- One focus of carcinoma is present which measures 7 mm in length and occupies 100% of the biopsy.

J. Right lateral base, biopsy:

- Prostatic parenchyma with adenocarcinoma, combined Gleason score 7 (4+3).
- One focus of carcinoma is present which measures 9 mm in length and occupies 100% of the biopsy.

K. Right lateral mid, biopsy:

- Prostatic parenchyma with adenocarcinoma, combined Gleason score 7 (4+3).
- One focus of carcinoma is present which measures 7 mm in length and occupies 100% of the biopsy.

L. Right lateral apex, biopsy:

- Prostatic parenchyma with adenocarcinoma, combined Gleason score 7 (4+3).
- One focus of carcinoma is present which measures 4 mm in length and occupies 100% of the biopsy.
- Focal high grade prostatic intraepithelial neoplasia.

COMMENT: The report was called to Dr. Kim's office 05/24/07, given to Edna and faxed.
 05/24/07 ML/jr

Mary L. Lynch, M.D. 24 MAY 2007
Report Electronically Signed

Clinical History:

PSA 22.0 on 4/27/07.

Microscopic Description:

A through L: Performed.
 05/24/07 ML/jr

CPT: 88305x12

Microscopic examination performed at CLIA (CLIA #45D0999132) approved facility located at 2727 W. Holcombe

End of Report