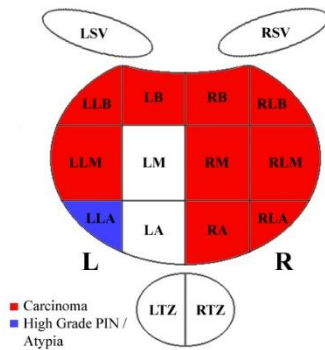


Accession Number <b>SB19-1</b>	DOB/Age/Sex 00/00/0000 (Age: 72) M	Page 1
Patient Name <b>Duck, Donald</b>	Patient ID # <b>None Provided</b>	Collected 01/02/2019
Requesting Physician/Report Sent To <b>UNKNOWN</b>		Received 01/02/2019
Facility ABC Urology Center		Reported 01/04/2020

## Surgical Pathology Report



Received in formalin and entirely submitted as: (nails / rv)

Block	Specimen Source	Number Pieces	Measurement
A.	LLB	1	0.7 cm.
B.	LLM	1	0.7 cm.
C.	LLA	1	1.0 cm.
D.	LB	1	0.7 cm.
E.	LM	1	0.8 cm.
F.	LA	1	0.6 cm.
G.	RB	1	0.9 cm.
H.	RM	1	0.5 cm.
I.	RA	1	0.5 cm.
J.	RLB	1	0.9 cm.
K.	RLM	1	0.7 cm.
L.	RLA	1	0.2 cm.

### Final Diagnosis:

#### A. Left lateral base, biopsy:

- Prostatic parenchyma with adenocarcinoma, combined score 7 (3+4).
- There is one focus of carcinoma which measures 2.5 mm in length and occupies 50% of the biopsy.

#### B. Left lateral mid, biopsy:

- Prostatic parenchyma with adenocarcinoma, combined Gleason score 6 (3+3).
- One focus of carcinoma is present which measures 1.5 mm in length and occupies 20% of the biopsy.

#### C. Left lateral apex biopsy:

- Prostatic parenchyma with focal glandular atypia, not diagnostic for malignancy.

#### D. Left base, biopsy:


- Prostatic parenchyma with adenocarcinoma, combined Gleason score 6 (3+3).
- One focus of carcinoma is present which measures 1 mm in length and occupies 10% of the biopsy.
- Perineural extension of carcinoma is identified.

#### E. Left mid, biopsy:

- Benign prostatic parenchyma.

#### F. Left apex, biopsy:

- Benign prostatic parenchyma.



**Brown & Associates**  
medical laboratories, L.L.P.

2525 W. Bellfort St., Ste. 120 Houston, TX 77054  
Tel: 713.741.6677 Fax: 713.748.5860

Accession Number <b>SB19-1</b>	DOB/Age/Sex 00/00/0000 (Age: 72) M	Page 2
Patient Name <b>Duck, Donald</b>	Patient ID # <b>None Provided</b>	Collected 01/02/2019
Requesting Physician/Report Sent To <b>UNKNOWN</b>		Received 01/02/2019
Facility <b>ABC Urology Center</b>		Reported 01/04/2020

## Surgical Pathology Report

### G. Right base, biopsy:

- Prostatic parenchyma with adenocarcinoma, combined Gleason score 7 (4+3).
- One focus of carcinoma is present which measures 7 mm in length and occupies 100% of the biopsy.
- Focal high grade prostatic intraepithelial neoplasia.

### H. Right mid, biopsy:

- Prostatic parenchyma with adenocarcinoma, combined Gleason score 7 (4+3).
- One focus of carcinoma is present which measures 5.5 mm in length and occupies 100% of the biopsy.

### I. Right apex, biopsy:

- Prostatic parenchyma with adenocarcinoma, combined Gleason score 7 (4+3).
- One focus of carcinoma is present which measures 7 mm in length and occupies 100% of the biopsy.

### J. Right lateral base, biopsy:

- Prostatic parenchyma with adenocarcinoma, combined Gleason score 7 (4+3).
- One focus of carcinoma is present which measures 9 mm in length and occupies 100% of the biopsy.

### K. Right lateral mid, biopsy:

- Prostatic parenchyma with adenocarcinoma, combined Gleason score 7 (4+3).
- One focus of carcinoma is present which measures 7 mm in length and occupies 100% of the biopsy.

### L. Right lateral apex, biopsy:

- Prostatic parenchyma with adenocarcinoma, combined Gleason score 7 (4+3).
- One focus of carcinoma is present which measures 4 mm in length and occupies 100% of the biopsy.
- Focal high grade prostatic intraepithelial neoplasia.

COMMENT: The report was called to Dr. Unknown's office 01/04/19, given to Micky Mouse and faxed.  
01/04/19 ML/ss



**Mary L. Lynch, M.D. 04 JAN 2019**  
**Report Electronically Signed**



**Brown & Associates**  
medical laboratories, L.L.P.

2525 W. Bellfort St., Ste. 120 Houston, TX 77054  
Tel: 713.741.6677 Fax: 713.748.5860

Accession Number <b>SB19-1</b>	DOB/Age/Sex 00/00/0000 (Age: 72) M	Page 3
Patient Name <b>Duck, Donald</b>	Patient ID # <b>None Provided</b>	Collected 01/02/2019
Requesting Physician/Report Sent To UNKNOWN		Received 01/02/2019
Facility ABC Urology Center		Reported 01/04/2020

## Surgical Pathology Report

### Clinical History:

PSA 22.0 on 12/04/19.

### Microscopic Description:

A through L: Performed.  
01/04/19 ML/ss

**CPT:** 88305x12

Microscopic examination performed at CLIA (CLIA #45D0999132) approved facility located at 2727 W. Holcombe

End of Report